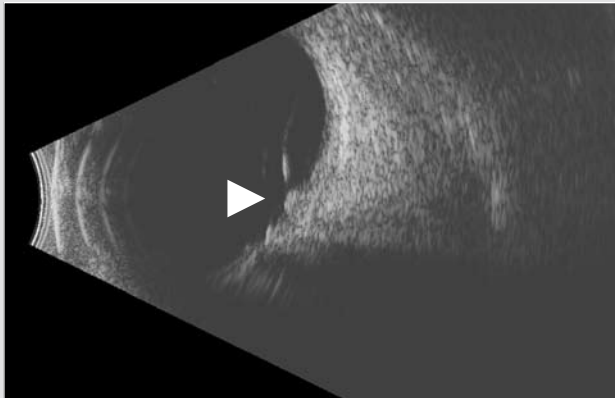
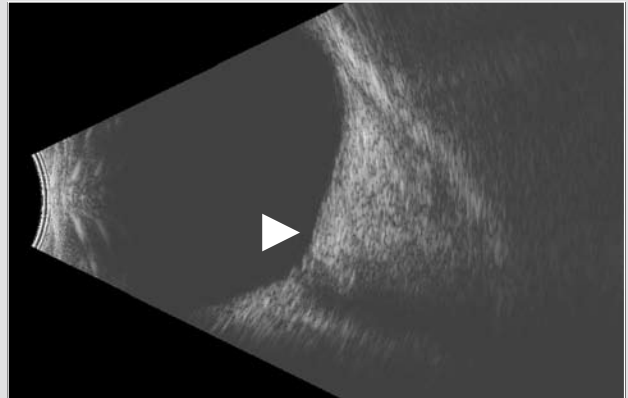


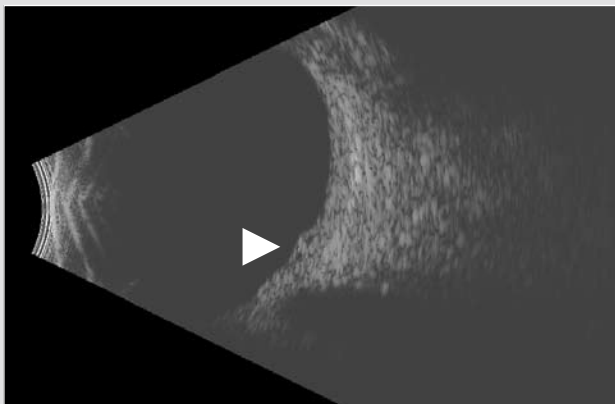
CASE STUDY THREE: 10 MHz B-Scan | Macular Pathology



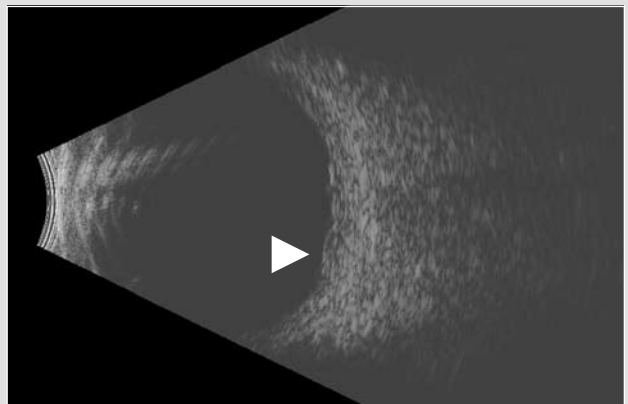
CME caused by Vitreo Macular Traction Syndrome
(Longitudinal Macula View) Posterior hyaloid inserts at nerve, fovea and equator



CME with no Vitreous Traction (Longitudinal Macula View)
Extensive edema altering globe contour; note optic cup



CRVO with Double Macular Cyst (Longitudinal Macula View)
Central Retinal Vein Occlusion



CRVO with Double Macular Cyst (Vertical Macula View)
Central Retinal Vein Occlusion

Headquarters

82 Gilbert Street
Adelaide, SA, 5000 AUSTRALIA
+61 8 8104 5200

Japan

4-3-7 Miyahara 4F, Yodogawa-ku
Osaka 532-0003 JAPAN
+81 6 6396 2250

USA

7138 Shady Oak Road
Minneapolis, MN, 55344 USA
1 800 824 7444

Europe Support Center

108, avenue Marx Dormoy
63000 Clermont-Ferrand FRANCE
+33 4 73 34 18 55