

Wavelength Selection

Retinal Photocoagulation: An Overview of Yellow, Red and Green Wavelengths

For several decades, laser photocoagulation has remained the mainstay of treatment for various retinal diseases. It offers a safe, non-invasive method of treating common retinal conditions, including proliferative diabetic retinopathy (PDR), diabetic macular edema (DME) and choroidal neovascularization in age-related macular degeneration (AMD).

INTRODUCTION

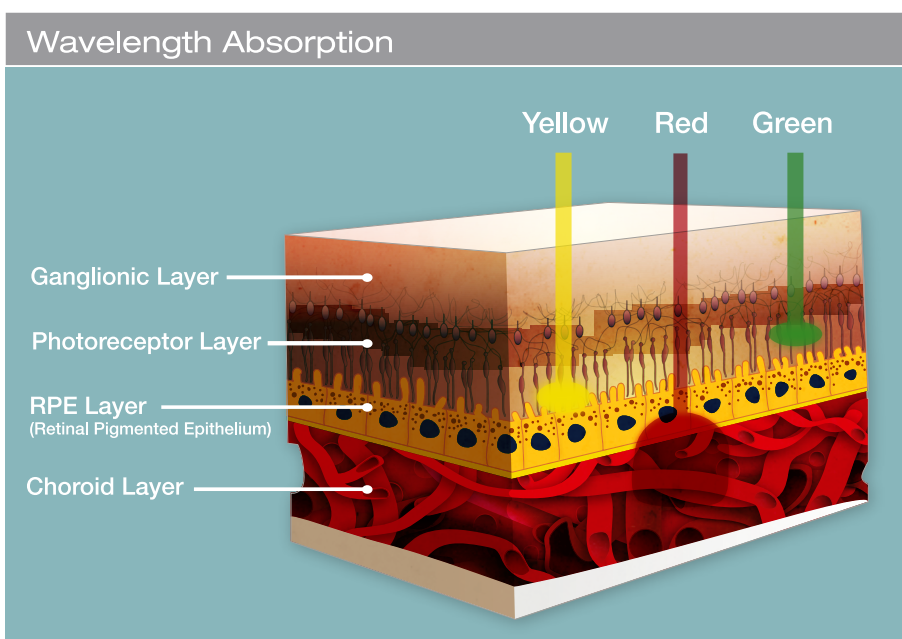
The most effective wavelengths for retinal photocoagulation are those which are poorly absorbed by macular xanthophyll, and maximally absorbed by melanin in the RPE and choroids, and by hemoglobin. The green wavelength, with its minimal absorption by xanthophyll and strong absorption in melanin and hemoglobin, has long been considered the “standard of care” for treatment of the retina

There are some limitations when using the green wavelength to treat in the

retina, however. Absorption occurs at the vitreous level in cases of vitreous hemorrhage, resulting in possible tissue damage and a decrease in energy available to produce the desired lesion. Furthermore, if a layer of blood is present in the inner layer of the retina, increased energy uptake is produced in the inner retina, preventing treatment of deeper structures, such as a subretinal neovascular membrane. As a result, use of both the yellow wavelength (561-577nm) and the red wavelength (659-670nm) to perform retinal treatment warrants further investigation.

THE YELLOW WAVELENGTH

The yellow wavelength (561-577nm) exhibits many similar characteristics to the green wavelength, and is suitable for performing all 514/532nm procedures, including iridotomy and laser trabeculoplasty if sufficient power is available. However, the yellow wavelength offers the added advantages of being effective at lower energy levels, improved patient comfort, less light scatter and less phototoxicity.



Yellow is ideal for treating clinically significant diabetic macular edema and juxtafoveal and extrafoveal choroidal neovascularization, as well as to perform grid pattern laser in eyes with branch retinal vein occlusion. In addition, given the high absorption of yellow in melanin, it can be considered in the treatment of some eyes with chronic central serous retinopathy.

Compared to the green wavelength, yellow exhibits similar high absorption in melanin and in hemoglobin, which allows for production of visible lesions with low energy settings. It also makes it more effective for the treatment of vascular structures. Unlike the 532nm wavelength, 561nm yellow is not absorbed in xanthophyll, produces less scatter and therefore is effective at lower energy levels.

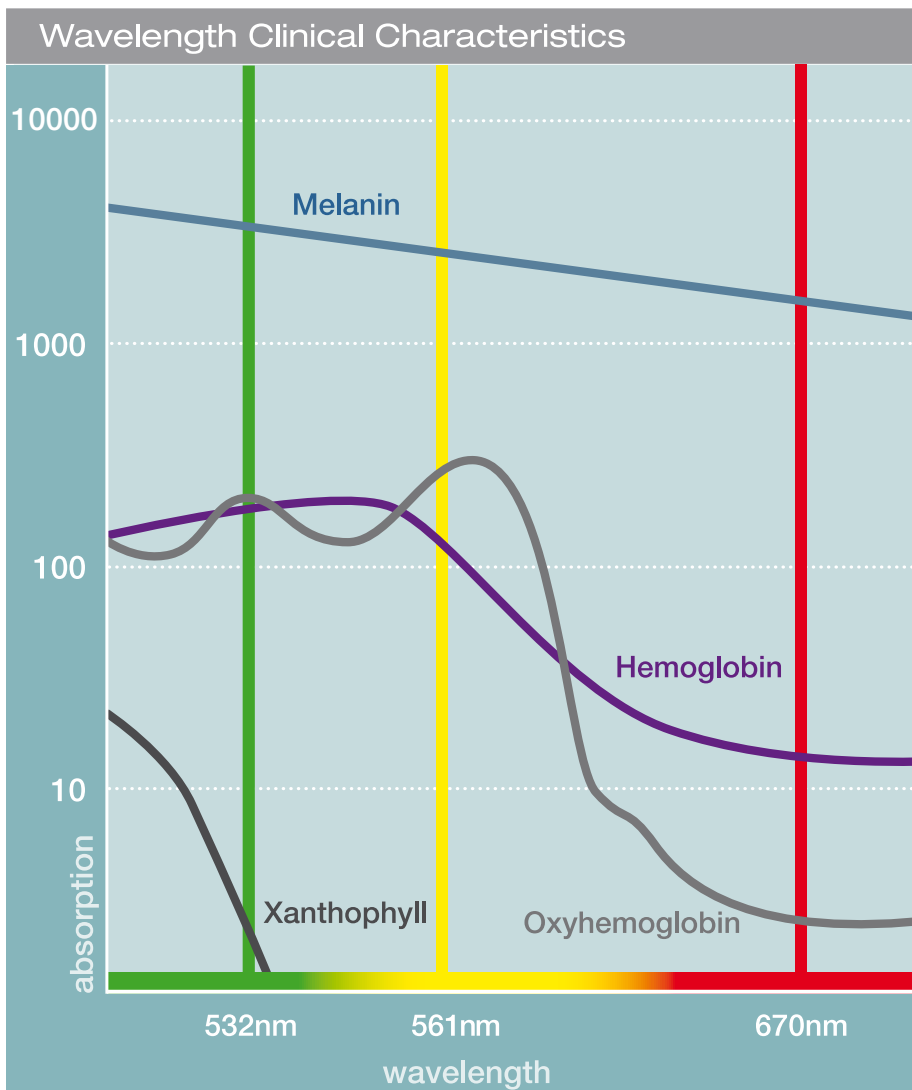
When treating inside the macular pigment area, yellow creates a more predictable, controlled burn than traditional 514/532nm green wavelengths, resulting in lower scotoma formation. The surgeon

has more precise control over the interaction between the laser beam and tissue, and can create a visible laser burn with less power and thus less injury to surrounding tissues than with the green wavelength.

Use of the yellow wavelength is also more comfortable for patients because there is less lateral as well as less axial spread of thermal energy. Because the yellow wavelength is well absorbed, the power and duration can be decreased and thus the patient is more comfortable.

As the yellow wavelength is longer there is less scatter, which provides for better transmission through lens opacities. As a result, yellow can be used effectively to treat through lenses with nuclear cataracts – using reduced energy levels.

There are a number of other instances in which the yellow wavelength is superior to the 514/532nm green wavelengths. Yellow is ideal for treating clinically significant diabetic macular edema and juxtafoveal and extrafoveal choroidal neovascularization, as well as to perform grid pattern laser in eyes with branch retinal vein occlusion. In addition, given the high absorption of yellow in melanin, it can be considered in the treatment of some eyes with chronic central serous retinopathy because the lack of yellow laser uptake by xanthophyll protects the fovea. The yellow wavelength may, in theory, be better suited for feeder laser photocoagulation in eyes with retinal angiomatous proliferans.



THE RED WAVELENGTH

The red wavelength has excellent properties for laser photocoagulation of the retina, providing deep, gentle penetration for effective treatment of choroidal vessels.

The absorption characteristics of the red wavelength (659-670nm) are very similar to those of the 647nm krypton laser. Producing less scatter for better transmission through a cloudy cornea or lens, the red wavelength also provides deeper penetration for effective treatment of choroidal vessels. It also enables treatment in the presence of a hemorrhage due to its lower absorption in haemoglobin.

While 532nm green is considered the “workhorse” wavelength and yellow is becoming more widely used, it is often helpful to have red available when faced with more challenging cases, such as vitreous hemorrhage – the red wavelength allows you to penetrate through the pre-retinal, sub-retinal or intra-retinal hemorrhage in order to treat the target tissue below. In addition, the red wavelength is beneficial when treating retinopathy of prematurity (ROP). Red is not absorbed by the macular xanthophyll pigment and can therefore be used for treatments in or around the macular area. It is also ideal for suture lysis.

REFERENCES

- 1 Mainster MA. Wavelength selection in macular photocoagulation. Tissue optics, thermal effects, and laser systems. Ophthalmology 1986;93:952-8.
- 2 Mainster MA. Decreasing retinal photocoagulation damage: principles and techniques. Semin Ophthalmol. 1999; 14: 200-209.
- 3 Meyer-Schwickerath GR. The history of photocoagulation. Aust N Z J. Ophthalmol. 1989; 17: 427-34.
- 4 Krauss JM, Puliafito CA. Lasers in ophthalmology. Lasers Surg Med 1995; 17: 102-59.



ellex.com

Headquarters

82 Gilbert Street
Adelaide, SA, 5000 AUSTRALIA
+61 8 8104 5200

Japan

4-3-7 Miyahara 4F, Yodogawa-ku
Osaka 532-0003 JAPAN
+81 6 6396 2250

USA

7138 Shady Oak Road
Minneapolis, MN, 55344 USA
800 824 7444

Germany

Edisonstraße 20
3512 Hainburg GERMANY
+49 6182 829 6900

Australia

Suite 2, Ground Floor, 18-20 Orion Road
Lane Cove, NSW, 2066 AUSTRALIA
1800 817 920

Europe Support Center

108, avenue Marx Dormoy
63000 Clermont-Ferrand FRANCE
+33 4 73 34 18 55